

**DETERMINATION OF ASPERGILLOSIS OF THE FEMALE GENITAL ORGANS  
IN WOMEN WITH IMMUNODEFICIENCY***Lytvynenko M.V.<sup>1</sup>, Bondarenko A.V.<sup>2</sup>, Bondarenko O.V.<sup>3</sup>, Gargin V.V.<sup>2</sup>, Katsap O.V.<sup>4</sup>*<sup>1</sup>**Odessa National Medical University, Odessa, Ukraine**<sup>2</sup>**Kharkiv National Medical University, Kharkiv, Ukraine**<sup>3</sup>**Kharkiv International Medical University, Kharkiv, Ukraine**<sup>4</sup>**MNPE "City Clinical Hospital No.1" of the Odessa City Council, Odessa, Ukraine**<https://doi.org/10.35339/ic.10.1.lbb>**ABSTRACT**

**Background.** Morphological diagnosis of aspergillosis sometimes poses great difficulties due to the fact that molds of the genus *Aspergillus* are very sensitive to the use of antimicrobial therapy and change under its influence. In this regard, we provide information about aspergillosis of the female genital organs, discovered accidentally during an autopsy.

The purpose of the study is to conduct a complex pathomorphological analysis of biopsy, operative and sectional gynecological material of women with secondary immunodeficiency conditions, for early diagnosis of aspergillosis (which is the key to a favorable outcome of the disease), differential diagnosis and detection of invasive forms of aspergillosis.

**Materials & Methods.** We analyzed the autopsies of 4,796 women who died in Odessa region from 2009 to 2022. Autopsies revealed 7 cases of aspergillosis with damage to the female reproductive system. All of them were found in women who had confirmed HIV infection. In 5 cases, women additionally suffered from chronic alcoholism.

**Results.** Based on the results of these cases, it can be stated that the detection of characteristic mycelium in the preparations is a reliable sign of aspergillosis, but their absence does not deny this disease. *Aspergillus* hyphae change as the process develops: they can be weakly stained, and with dystrophic phenomena and the presence of necrotic fragments of mycelium, it can be almost colorless when using hematoxylin and eosin. While necrosis, tissue detritus is observed in the center of the granuloma, fibrous structures, fungal hyphae are formed perifocally. To confirm the diagnosis, it is important to detect granulomatous productive inflammation, conidial heads, inflammatory infiltration, microabscesses, foci of calcifications. However, against the background of immunodeficiency, it is not always possible to see the "classic morphological picture" of aspergillosis. In addition, detection of characteristic mycelium is possible only in a proportion of patients.

**Conclusions.** When examining the autopsy material of deceased women with immunodeficiency states, attention should be paid to the specific etiology of inflammatory processes of the reproductive system and the nature of the inflammatory process, the presence of *Aspergillus* hyphae and mycelia. The presence of morphological changes characteristic of aspergillosis allows to conduct a diagnostic search in the right direction. Detection of an invasive form of aspergillosis may indicate the presence of an immunodeficient state.

**Keywords:** *aspergillosis, female reproductive system, immunodeficiency state, HIV infection, uterus, mammary gland, drug addiction.*

---

**Corresponding author:**

Lytvynenko Marianna – Candidate of Medical Sciences, Associate Professor of the Department of Normal and Pathological Clinical Anatomy of Odessa National Medical University.

Address: Ukraine, 65000, Odessa, Valikhovsky lane, 2, ONMedU. E-mail: lytvynenko\_marianna@ukr.net

**Introduction**

In recent years, an increase in immunodeficiency states has been noted in Ukraine [1]. The presence of an immunodeficiency condition affects a woman's body [2; 3], in particular, such women with immunodeficiency conditions are twice as likely to have pathological processes in the genital organs,

namely: dysfunctional uterine bleeding, endometrial hyperplasia, endometrial atrophy, pelvioperitonitis, actinomycosis of the uterus and appendages, dissemination of mycobacterium tuberculosis in the uterus and appendages, aspergillosis of the uterus and appendages, disseminated candidiasis, disseminated pneumocystosis, lymphoma, ovarian cystadenocarcinoma, squamous cell carcinoma of the cervix, acute and chronic non-specific salpingo-oophoritis, acute non-specific endometritis, cervical intraepithelial neoplasia, sclerocystic syndrome.

The course of the infectious process against the background of immunodeficiency has an atypical character. One of these processes is aspergillosis, which in the presence of an immune imbalance often takes on generalized forms [4].

**The purpose** of this work was to provide information about aspergillosis of the female genital organs, which was discovered accidentally during an autopsy.

#### **Materials & Methods**

To achieve this goal, we analyzed the autopsies of 4,796 women who died in Odesa region between 2009 and 2022. During this period, autopsies revealed 7 cases of aspergillosis with damage to the female reproductive system. All of them were found in women who had confirmed HIV infection. In 5 cases, women additionally suffered from chronic alcoholism. HIV infection was verified by enzyme-linked immunosorbent assay (ELISA). Chronic alcoholism was verified on the basis of catamnesis data and the establishment of alcoholic cirrhosis of the liver. In two cases, there was no prenatal data on the presence of aspergillosis. All autopsies were conducted in accordance with the order of the Ministry of Health of Ukraine (No.81 dated on May 12, 1992, and No.1877 dated on September 06, 2021). Pieces of organs were fixed in 10% neutral formalin, further processed according to generally accepted methods, and embedded in paraffin. Thickness sections were obtained on a microtome  $5 \times 10^{-6}$  m, which were placed on glass and stained with hematoxylin and eosin. To confirm aspergillosis, the sections were additionally stained by Shabadash, Foot's silvering. After identifying the morphological pattern characteristic of aspergillosis, the material was sent to the bacteriological center, where the presence of *Aspergillus spp.* was determined.

#### **Results**

We cite cases in which no lifetime data on the presence of aspergillosis were established.

Patient M., born in 1979, HIV-infected since 2004. She suffered from lymphoma for five years and underwent multiple courses of polychemotherapy. Remissions were short-lived. She was admitted to the hospital with complaints of headache, general weakness, low-grade fever. The examination revealed generalized lymphadenopathy, progression of the underlying disease with leukemia. The patient died 11 days after hospitalization. At the autopsy, the diagnosis of HIV infection, stage IV, terminal stage of lymphoma was confirmed, and generalized aspergillosis with lesions of the lungs, lymph nodes, brain, vagina, uterus was also revealed (*Fig.*).

Patient Z., born in 1973, has been taking narcotic drugs for 10 years, HIV-infected since 1999. She did not seek medical help. She died at her place of residence. HIV infection, stage IV, was detected at the autopsy; generalized aspergillosis: aspergilloma of lungs, mammary gland, vasculitis and thrombovasculitis of pulmonary vessels, aspergillosis abscesses of lymph nodes, aspergillosis sepsis. Among other AIDS-indicative diseases, candidal erosive esophagitis and bacterial pneumonia are documented.

The described observations illustrate the presence of different forms of aspergillosis (invasive and non-invasive) in persons with secondary severe immunodeficiency. At the same time, in both cases, the most affected organ of the female reproductive system was the uterus (*Fig.*). In both cases, the diagnosis was established only during the study of autopsy material. In both cases, histological examination of the endocervix and endometrium revealed the presence of fungal structures in the form of branched septate hyphae together with conidial forms, with ingrowth into the mucous membrane, with foci of necrosis. This was the basis for sending the material to the bacteriological laboratory, where the presence of *Aspergillus spp.* was established.

#### **Discussion**

The course of any pathological process against the background of immunodeficiency often has unexpected clinical manifestations. It is known that the presence of actinomycosis of the uterus and appendages, tuberculosis of the genital organs, aspergillosis, disseminated candidiasis, and pneumocystosis is significantly more frequent in HIV-infected patients [5–7]. While we found descriptions of only isolated cases of aspergillosis with extrapulmonary localization [8–10].

In the structure of chronic inflammatory gynecological diseases of the uterus, an additional



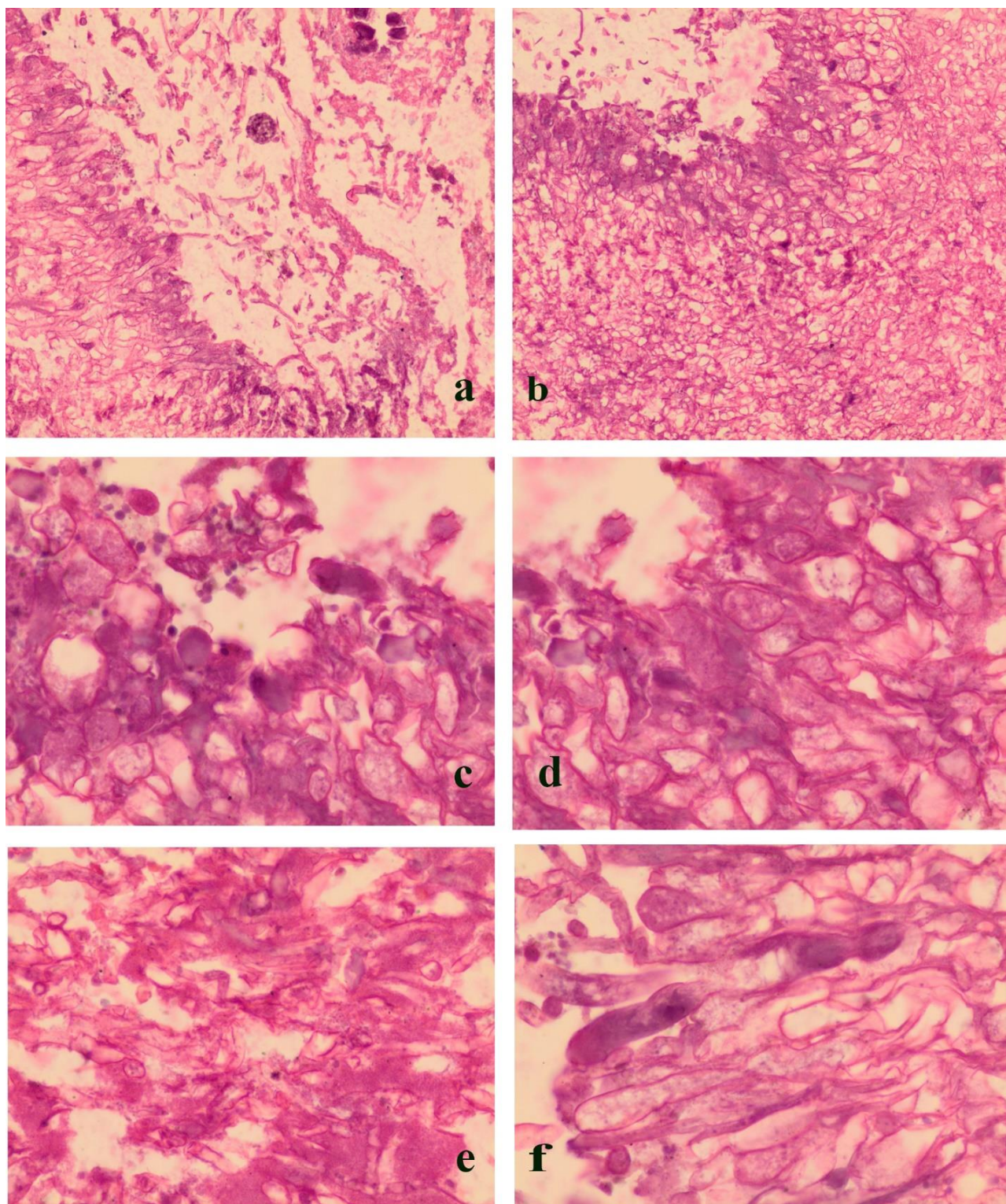


Fig. Aspergillosis of the female reproductive system: a) the presence of an *Aspergillus* conidial head in the center of the detritus when the uterus is affected. Magnification  $\times 100$ ; b) Multiple *Aspergillus* hyphae in the uterus. Magnification  $\times 100$ ; c, d) Radial arrangement of hyphae of the genus *Aspergillus* in the uterus. Magnification  $\times 400$ ; e) The presence of aspergillus mycelium in the center of mammary gland necrosis during the development of sepsis. Magnification  $\times 400$ ; f) aspergillosis salpingitis. Magnification  $\times 400$ .

place is occupied by aspergillosis. Aspergillosis of the pelvic organs in women is also characterized by a long-term progressive course that leads to multiorgan complications.

Diagnosis of genital aspergillosis, as a rule, is based on the results of a histological examination of the surgical material, it is quite informative and important for differential diagnosis. However, the morphological diagnosis of aspergillosis sometimes presents greater difficulties due to the fact that aspergillus is very sensitive to the use of antibacterial drugs. Therefore, this disease remains undiagnosed during life. In this regard, when making a diagnosis, along with light electron microscopy and examination of micropreparations stained with hematoxylin and eosin, it is necessary to use additional research methods.

Detection of characteristic hyphae and mycelia of *Aspergillus* in preparations is the most reliable factor in the diagnosis of the disease. The cellular composition of a granuloma changes as the process of their development progresses. While necrosis is observed in the center of the granuloma, fibrous structures, xanthoma cells are formed peripherally. For diagnosis, it is also important to detect granulomatous productive inflammation, leukocyte infiltration, microabscesses, "cellular" tissue structure, specific granulomas that are surrounded by polynuclear, giant and plasma cells, lymphocytes and histiocytes. However, against the background of immunodeficiency, it is not always possible to see the "classic morphological picture" of aspergillosis. In addition, the detection of drusen is possible only in 25–60% of patients with actinomycosis, since these organisms are able to spontaneously lyse, calcify, deform and undergo

other degenerative changes. The use of separate staining methods for diagnosis of aspergillosis does not always allow to increase the percentage of its detection. Considering the unfavorable state of reproductive health of women in Ukraine [11–13], we believe that the given data will help to establish a timely diagnosis and prescribe adequate treatment.

### Conclusions

When examining the autopsy material of deceased women with immunodeficiency states, attention should be paid to the specific etiology of inflammatory processes of the reproductive system and the nature of the inflammatory process, the presence of *Aspergillus* hyphae and mycelia. The presence of morphological changes characteristic of aspergillosis allows you to conduct a diagnostic search in the right direction. Detection of an invasive form of aspergillosis may indicate the presence of an immunodeficient state.

### DECLARATIONS:

#### Disclosure Statement

The authors have no potential conflicts of interest to disclosure, including specific financial interests, relationships, and/or affiliations relevant to the subject matter or materials included.

#### Data Transparency

The data can be requested from the authors.

#### Statement of Ethics

The authors have no ethical conflicts to disclosure.

#### Funding Sources

There are no external sources of funding.

#### Consent for publication

All authors give their consent to publication.

Received: 05 May 2023

Accepted: 22 Jun 2023

### References

1. Krysko MO. Development of HIV-infection epidemic in Ukraine. Ukraine. The health of the nation. 2011;4(20):36-40. [In Ukrainian].
2. Demirdag Y, Fuleihan R, Orange JS, Yu JE. New primary immunodeficiencies 2021 context and future. *Curr Opin Pediatr.* 2021;33(6):657-75. DOI: 10.1097/MOP.0000000000001075. PMID: 34670265.
3. Lytvynenko MV, Gargin VV. Triple-negative transformation of the endometrium, cervix and mammary gland on the background of immunodeficiency. *Med Perspekt.* 2022;27(2):119-24. DOI: 10.26641/2307-0404.2022.2.260284.
4. Houbraken J, Kocsube S, Visagie CM, Yilmaz N, Wang XC, Meijer M, et al. Classification of *Aspergillus*, *Penicillium*, *Talaromyces* and related genera (Eurotiales): An overview of families, genera, subgenera, sections, series and species. *Stud Mycol.* 2020;95:5-169. DOI: 10.1016/j.simyco.2020.05.002. PMID: 32855739.
5. Francini B, Canepa MC, Lamonica C, Capece P, Posse G, Sanguineri V, et al. Histoplasmosis diseminada. Una infección oportunista en pacientes con infección por VIH. Experiencia en el Hospital Nacional Prof. A. Posadas, 2011–2017 [Disseminated histoplasmosis. An opportunistic infection in HIV positive patients Experience in the Hospital Nacional Prof. A. Posadas, 2011–2017]. *Rev Chilena Infectol.* 2018;35(6):671-9. DOI: 10.4067/S0716-10182018000600671. PMID: 31095188. [In Spanish].



6. Mendez-Samperio P. Diagnosis of Tuberculosis in HIV Co-infected Individuals: Current Status, Challenges and Opportunities for the Future. *Scand J Immunol.* 2017;86(2):76-82. DOI: 10.1111/sji.12567. PMID: 28513865.
7. Stepanova TV, Nedospasova OP, Golubchikov MV. Analysis of tuberculosis/hiv co-infection trends in Ukraine in 2008-2017. *Wiad Lek.* 2019;72(5 cz 1):903-7. PMID: 31175793.
8. Borsa BA, Ozgun G, Houbraken J, Okmen F. İmmün kompetan bir hastada *Aspergillus protuberus*'un neden olduğu ilk inatçı vajinit olgusu [The first case of persistent vaginitis due to *Aspergillus protuberus* in an immunocompetent patient]. *Mikrobiyol Bul.* 2015;49(1):130-4. DOI: 10.5578/mb.8397. PMID: 25706739. [In Turkish].
9. Jia J, Chen M, Mo X, Liu J, Yan F, Li Z, Xie S, Chen D. The first case report of kerion-type scalp mycosis caused by *Aspergillus protuberus*. *BMC Infect Dis.* 2019;19(1):506. DOI: 10.1186/s12879-019-4144-7. PMID: 31182059.
10. Sun B, Luo C, Bills GF, Li J, Huang P, Wang L, et al. Four New Species of *Aspergillus* Subgenus *Nidulantes* from China. *J Fungi (Basel).* 2022;8(11):1205. DOI: 10.3390/jof8111205. PMID: 36422028.
11. Antypkin YG, Gorban NEY, Borysiuk OY, Lynchak OV. The reproductive health of the female residents in the areas of Ukraine affected by the radioactive contamination (2007–2017). *Probl Radiatsiinoi Med Radiobiologii.* 2019;2019(24):284-95. DOI: 10.33145/2304-8336-2019-24-284-295. PMID: 31841474. [In English, in Ukrainian].
12. Lyngso J, Ramlau-Hansen CH, Hoyer BB, Stovring H, Bonde JP, Jonsson BA, et al. Menstrual cycle characteristics in fertile women from Greenland, Poland and Ukraine exposed to perfluorinated chemicals: a cross-sectional study. *Hum Reprod.* 2014;29(2):359-67. DOI: 10.1093/humrep/det390. PMID: 24163265.
13. Zhylka NY, Slabkiy GO, Shcherbinska OS. The state of female reproductive health in Ukraine (literature review). *Reprod Endocrinol.* 2021;(60):67-71. DOI: 10.18370/2309-4117.2021.60.67-71. [In Ukrainian].

**Cite in Vancouver style as:** Lytvynenko MV, Bondarenko AV, Bondarenko OV, Gargin VV, Katsap OV. Determination of aspergillosis of the female genital organs in women with immunodeficiency. *Inter Collegas.* 2023;10(1):15-9. <https://doi.org/10.35339/ic.10.1.lbb>

**Creative Commons license (BY-NC-SA)** Lytvynenko M.V., Bondarenko A.V., Bondarenko O.V., Gargin V.V., Katsap O.V., 2023